

# CLINICAL REPORTS & TECHNIQUES

## *Matters of Education*

It was brought to my attention that the focus of my last editorial could be read differently than I had intended: taking potshots at other businesses. This is most unfortunate. Upon re-reading the editorial piece with this alert in mind, I can see why some of my long-time friends have expressed concern; I regret the accidental lack of an unequivocal focus. The intended message was that, since its inception, Align Technology has always been a tenacious partner of the educational establishment. Such perseverance speaks to the strength of the original foundation and vision of the company.

The business of education is not doing well; educators are put in a position to do more with less. Yet the demand for education is at an all-time high. Amusingly, the sequence of events in the life of a generic orthodontist is rather predictable: at the application stage, they all beg and promise. And the day after graduation, all is forgotten. In time, many become members of professional organizations and start making disparaging comments about the educational establishment. Close to home, at the AAO level, the president's proposal to subsidize orthodontic education is tabled; in contrast, Align Technology is working hard to integrate the Invisalign® system into the educational curricula. Whereas a number of companies are asking for the time of residents and the free-of-charge use of conference room facilities to market their goods,

Align Technology is providing free Invisalign treatment. While CE courses teach a particular orthodontic technique to be a source of profit for the organizers, Align Technology freely educates the clinician at all levels through online clinical education or telephone support from experts.

Integration of the Invisalign system into the predoctoral curricula is a good thing. It provides patient care service and education in the latest technology. Orthodontic departments in those institutions where integration has taken place now have access to a larger pool of patients. And for the private practitioner, a dentist who is knowledgeable in the Invisalign system makes the strongest referrals. I speak from experience.

This is like the old story of involvement and commitment. Whereas, the hen who lays the egg is involved in feeding the human kind, the pig is committed to providing a healthy breakfast. While many are seemingly involved, Align Technology has made a commitment to education and to the future of orthodontics. This is why the editorial in the spring issue of *Clinical Reports & Techniques* wanted to recognize Align Technology for its commitment to education since inception, while many others remain at facsimile-level involvement. Again, I regret any potential misunderstanding it might have caused among the individuals, new and established businesses.



Orhan C. Tuncay, DMD  
Editor

## CLINICAL REPORT

by David Paquette, DMD

The following two case reports will illustrate the utility of beveled attachments to control tooth positions, especially anterior teeth, and to finish the treated case to acceptable esthetic standards. (See Figure 1.)

The first patient is a 43-year-old female whose chief complaint was crowding of her front teeth. Clinically, she presented with a Class I malocclusion, moderate crowding, slightly deep overbite and slightly excessive overjet. She had good incisor display and a consonant smile arc. Periodontal health was good, but she had some slight gingival recession in the lower arch with

thin labial tissues. Of interest was a completely formed impacted supernumerary lower left second premolar. The decision was made to leave it as is unless a problem arose.

Her treatment plan was for full treatment. Objectives in the upper arch were to move posterior teeth distally, mild dental expansion, and modest anterior interproximal reduction. In the lower, appropriate posterior expansion was prescribed to match upper teeth. The patient was informed that the rotations in the upper incisors may require auxiliaries to complete treatment.

### Case 1, Initial Photos

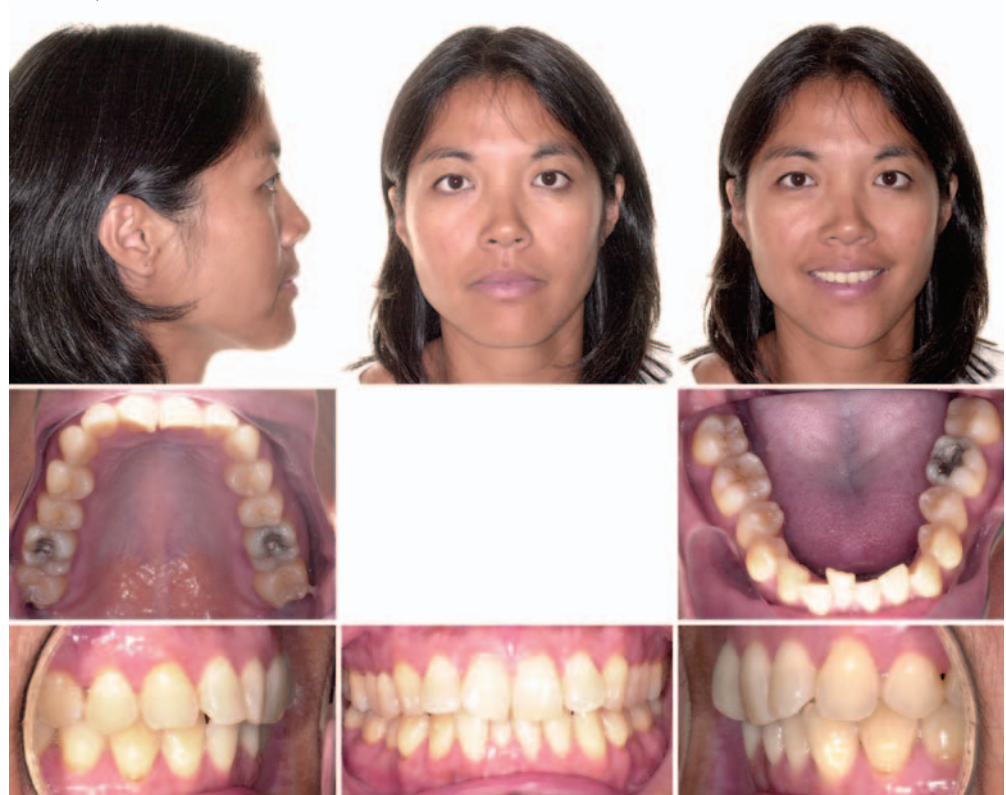
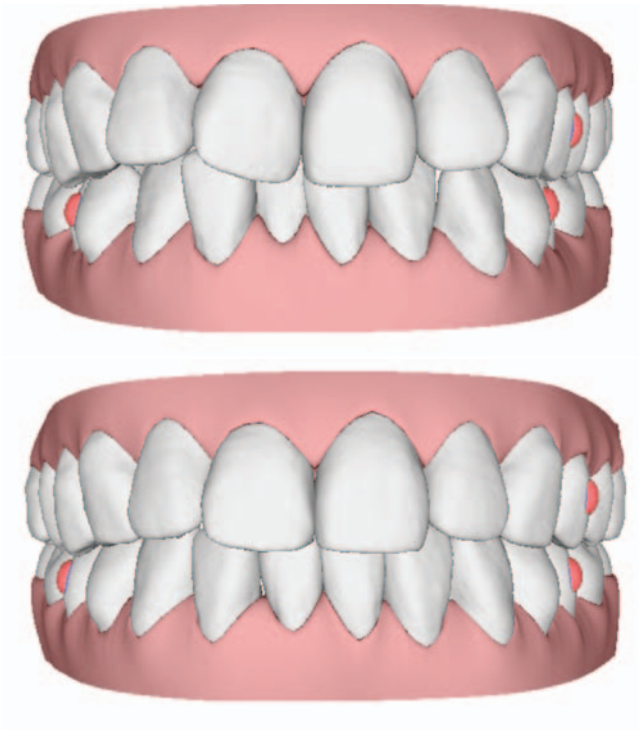
Figure 1. Female (age 43 years, 6 months) with Class I malocclusion, moderate crowding, slightly deep overbite and slightly excessive overjet.



Figures 2a, 2b. The initial ClinCheck® called for 27 aligners in both arches with upper anterior interproximal reduction. Attachments were placed and the initial series of 6 sets of aligners were delivered. The patient was seen again in 12 weeks at which time treatment was progressing normally; initial interproximal reduction was started and sets 7–12 were delivered and the patient reappointed for 12 weeks. The patient returned, treatment was progressing normally, more interproximal reduction was performed and sets 13–18 were delivered and the patient reappointed again for 12 weeks. At the next visit interproximal reduction was completed; however, slight gingival recession was noted in the lower arch so the patient was given only 3 sets and reappointed for 6 weeks.

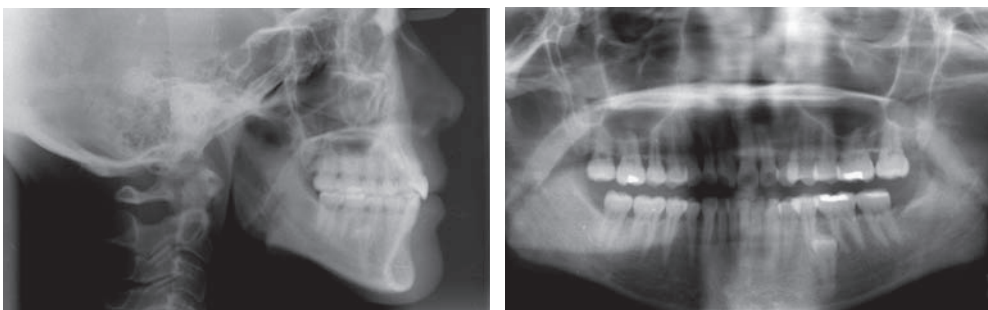
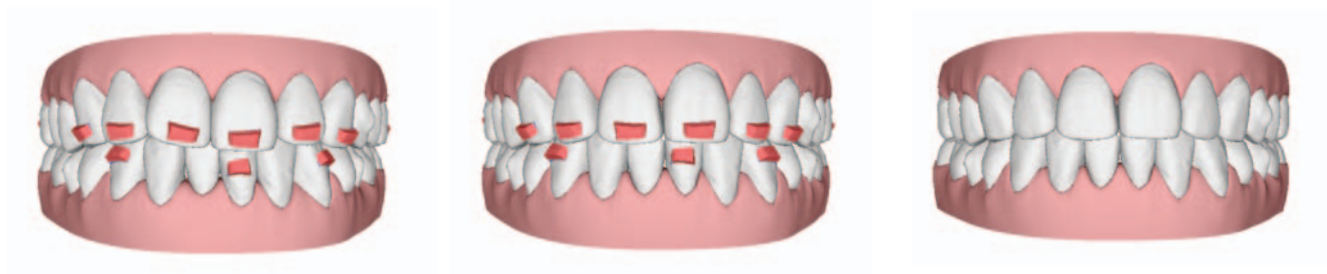


Figure 3. Case 1, initial: Cephalometric radiograph shows nice facial balance and incisor inclination with slightly excessive overbite. The panoramic film reveals a supernumerary lower left second premolar that the patient reported never having any discomfort and the consultant oral surgeon recommended observation. The panoramic film also revealed prior mild horizontal bone loss in molar regions.

When the patient returned at stage 22 it was noted that the anterior teeth were not seating well so the decision was made for a midcourse correction. During the course of this next phase of treatment, anterior tooth positions were to be corrected with beveled attachments. The patient was instructed to stay in her last active aligner until refinement aligners could be delivered.

Clinical Report (Paquette) continued

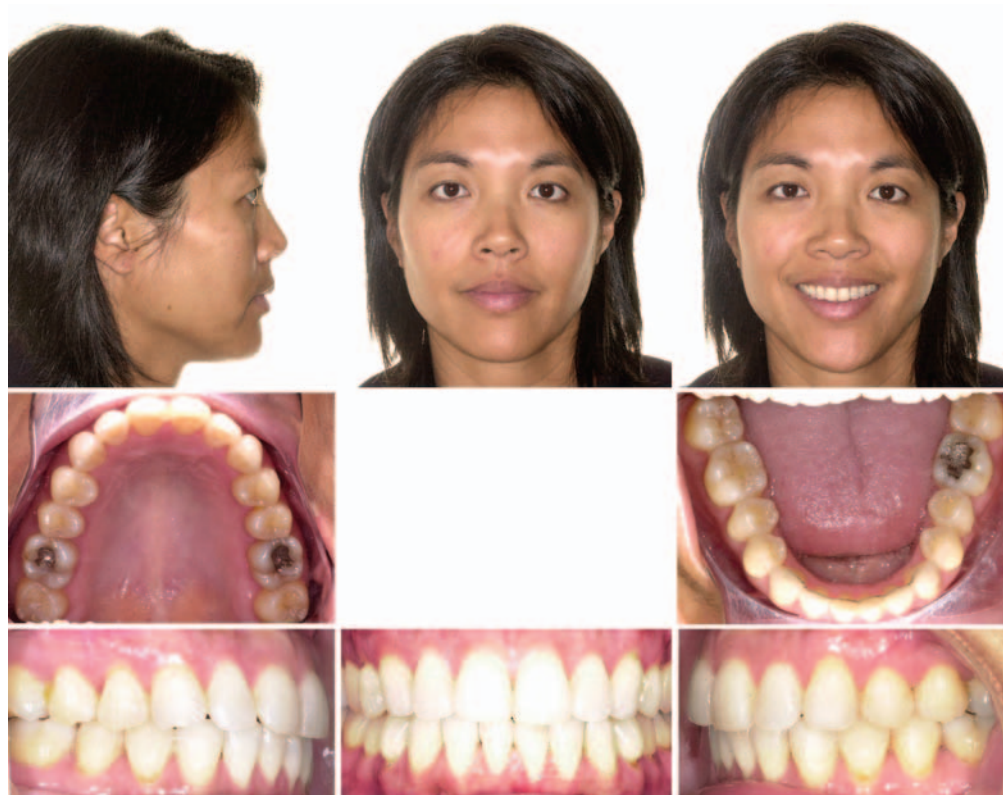

Figures 4a, 4b, 4c. The patient returned 7 weeks later and beveled attachments were placed. The refinement prescription called for 9 additional sets and no additional interproximal reduction. The patient was given 6 sets and scheduled to return in 12 weeks. She returned one week later with one attachment

off and it was repaired. At the following appointment, the final 3 sets of aligners were delivered. The patient returned in 6 weeks, attachments were removed, a lower anterior bonded retainer placed, and upper Essix<sup>®</sup> retainer delivered.

Case 1, Final Photos

Figure 5. Case 1, final photos. Total treatment time 16 months, 30 aligners, 21 initial and 9 refinement.



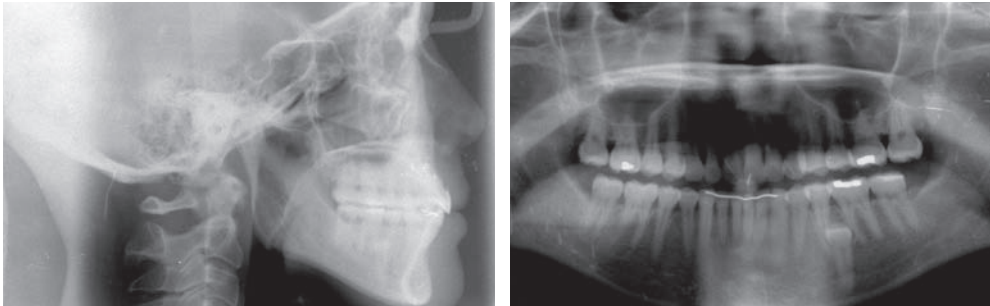


Figure 6. Case 1, final: Cephalometric film shows improvement in overbite and minimal proclination of the lower incisors. Panoramic film shows no change in the supernumerary tooth position and no evidence of additional bone loss.

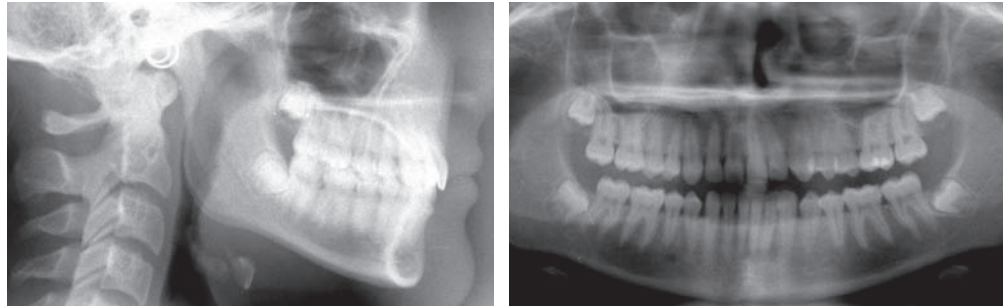
### Case 2, Initial Photos

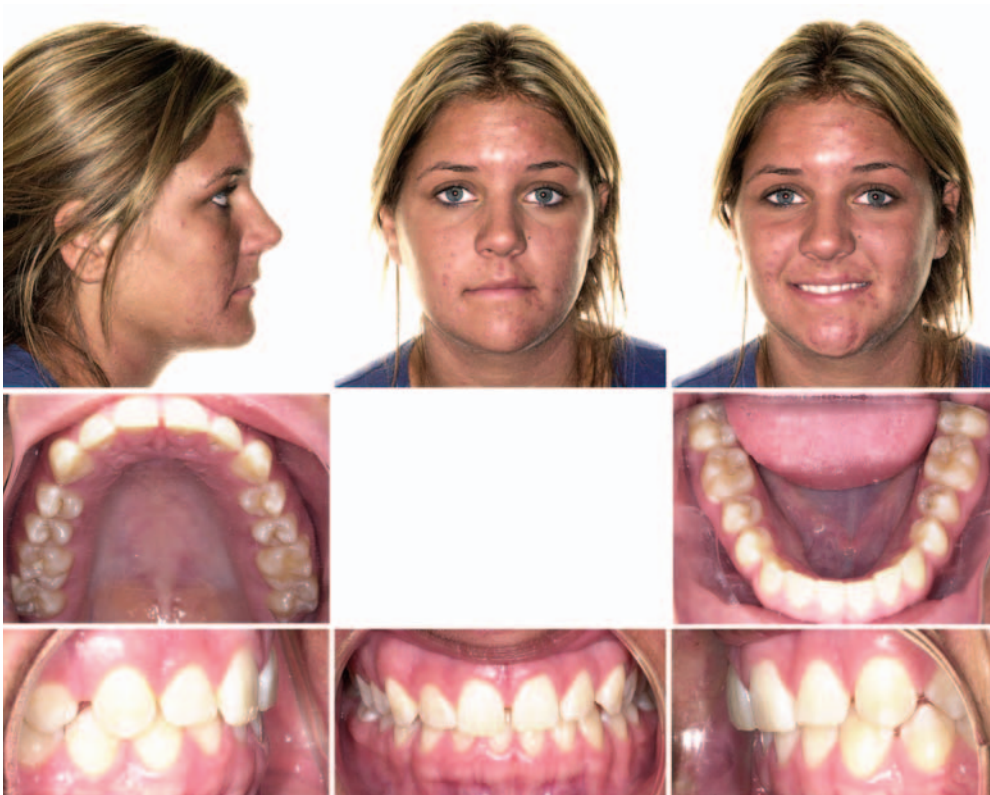

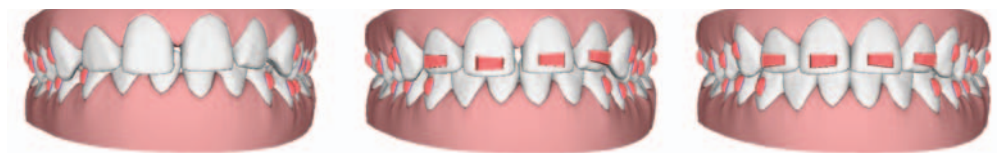
Figure 7. The second patient was a 17-year-old female unhappy with the spacing of her front teeth. Clinically, she exhibited Class I occlusion, moderate spacing on the upper, significantly deep overbite and slightly excessive overjet. The upper midline was to the right 1–2 mm. She had good incisor display and a consonant smile arc. Periodontal health was good. Her upper incisors were slightly upright.

Clinical Report (Paquette) continued

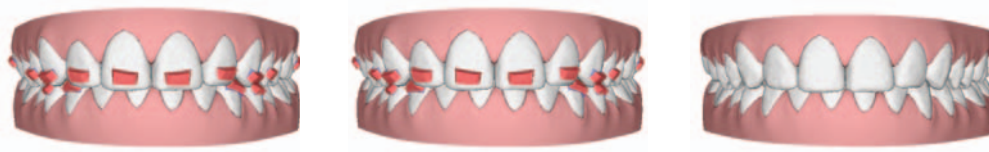Figure 8. Case 2, initial: Cephalometric film shows deep overbite and upright upper incisors. The panoramic film shows normally developing third molars and no other significant findings.



Her treatment plan with Invisalign was for full treatment. Objectives were to close maxillary spacing and to level the lower arch. Lower arch interproximal reduction was prescribed to aid in closing the upper arch spacing. When informed that attachments would be required to maintain torque in upper anteriors, the patient requested that the attachments on her upper incisors be delayed as long as possible.



Figures 9a, 9b, 9c. The initial ClinCheck® called for 26 upper aligners and 19 lower. Upper anterior interproximal reduction was needed to correct the left-to-right anterior tooth size discrepancy. Attachments were placed on posterior teeth and the initial series of 6 sets of aligners were delivered. The patient was seen again in 12 weeks at which time treatment was progressing normally, initial interproximal reduction was started and sets 7–12 were delivered and the patient reappointed for 12 weeks. The patient returned, treatment was progressing normally, anterior attachments were placed and aligners 13–18 were delivered for 12 weeks. At the next visit interproximal reduction was completed and the patient was given her final lower aligner and the next 6 upper aligners. She was reappointed for 12 weeks. She was told to wear the lower aligner full time for 4 weeks and then at night only until the next visit.



Figures 10a, 10b, 10c. When the patient returned at stage 26 it was noted that the anterior teeth required additional lingual root torque and that the patient had not worn the lower aligner for some time. The decision was made to obtain new impressions and do refinement with beveled attachments to help control anterior tooth positions. All attachments were removed and new impressions were made. The patient was instructed to stay in aligner 26 on the upper until refinement aligners could be delivered; then she lost it the following week and was instructed to wear number 25.

The patient was scheduled to return in 4 weeks but rescheduled the appointment and returned 8 weeks later and beveled attachments were placed. The refinement prescription called for 14 additional sets and no additional interproximal reduction. The patient was given 6 sets and scheduled to return in 12 weeks. She returned 4 weeks later and decided that she was happy with the alignment of her teeth and requested that treatment be terminated at that point. Attachments were removed, an upper 1-1 and lower 3-3 anterior bonded retainers placed and upper Essix® retainer delivered. Her treatment lasted 16 months.

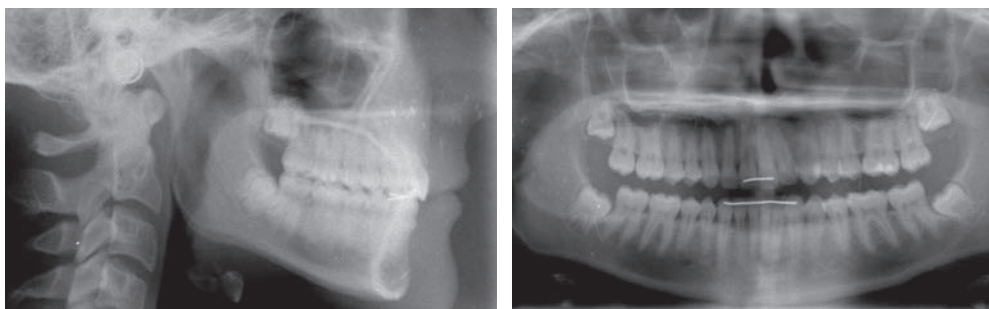


Figure 11. Case 2 final: Headfilm shows some improvement in overbite and lack of torque correction in upper incisors as a result of patient terminating treatment.

Clinical Report (Paquette) continued

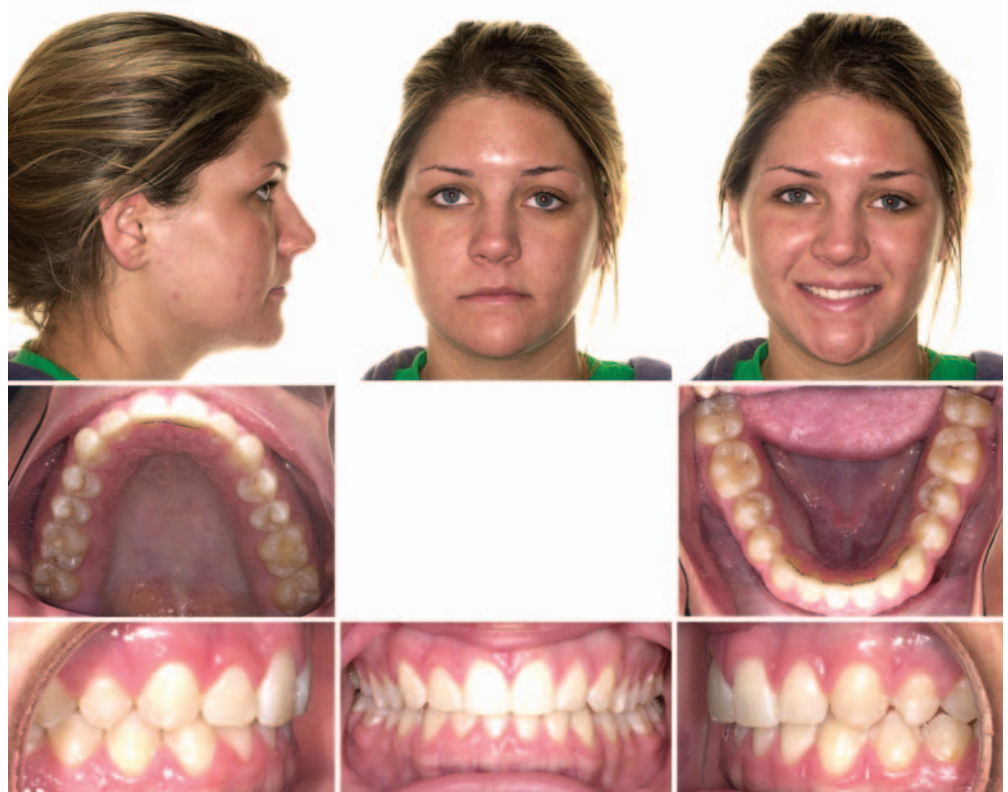

Figure 12. Case 2, final photos.

## CLINICAL REPORT

by Jonathan L. Nicozisis, DMD, MS

Worldnet.princeton.edu defines *attachment* as the “faithful support of a religion or cause or political party.” Arguably, the advent of clear removable appliances moved clinicians and academics alike, to choose sides and “attach” their beliefs or reputations to support one side or the other. Indeed, true to form, orthodontists still passionately debate the merits and demerits of clear removable appliances as if geopolitical consequences are at stake.

The same website also defines *attachment* as “a supplementary part or accessory.” As an “accessory” to the Invisalign® system, attachments can range from quite simple to elaborate; customized works of art that are born from the minds of clinicians willing to think outside the box. Certainly, the Invisalign clinician knows all too well the quest for the ultimate attachment which will deliver all the predictable and precise tooth movements.

Good data came out of University of Florida clinical trials that tested the efficacy of various attachments to accomplish specific movements, but since the start of those studies new ideas in attachment design have come forth. Here we will discuss the “ramped” attachment.

“*Ramped attachment*: horizontal rectangular 2.50 mm wide, 1.50 mm high, 1.25 mm thick at the incisal margin tapering to a thickness of 0.50 mm at the gingival margin. Place at the junction of the middle and incisal thirds” is how I communicate the design via the special instructions section during my case submission. The attachment is placed at the junction of the middle and incisal thirds because closer to the incisal edge the aligner material becomes stiffer. Around the gingival third the material tends to

get flimsy and does not grab the tooth or attachment decisively. This design concept has been described by others.

It is best to ramp (bevel) the attachments thicker at the incisal edge and taper to a thinner profile at the gingival. (See *close-up images of ramped/beveled attachments in Fig 2c.*) Others have described beveled attachments with opposite characteristics: thicker at the gingival edge and thinner at the incisal. Unfortunately, experience shows attachments of this configuration become ineffective once these attachments cease to track fully. In fact, they cause a tooth to intrude. Clearly, in an extrusion case this is undesirable.

The preferred design used here moves a tooth in the prescribed direction better as it allows constant contact between the beveled surface and the aligner. It may be posited that the design is effective because it creates an angle that contrasts the lingually-tapering nature of a clinical crown in the incisal third. Whereas, in the flipped-around design the ramped portion tapers in the *same* direction as the clinical crown; thus, decreasing any effectiveness in the aligner “clipping” onto the attachment. Once the incorrectly configured attachment slips contact, it suddenly becomes a wedge to reverse the direction of tooth movement: from extrusion to intrusion.

### Case 1: Extrusion

Crowding is not a good indication for IPR. Only indications for IPR may be: 1) sizeable Bolton discrepancy, or 2) to correct minor Class III cases. It has long been known spacing cases work best with the Invisalign system; thus, it is best to turn a crowded case into minor spacing case. Accordingly, tooth movements must be

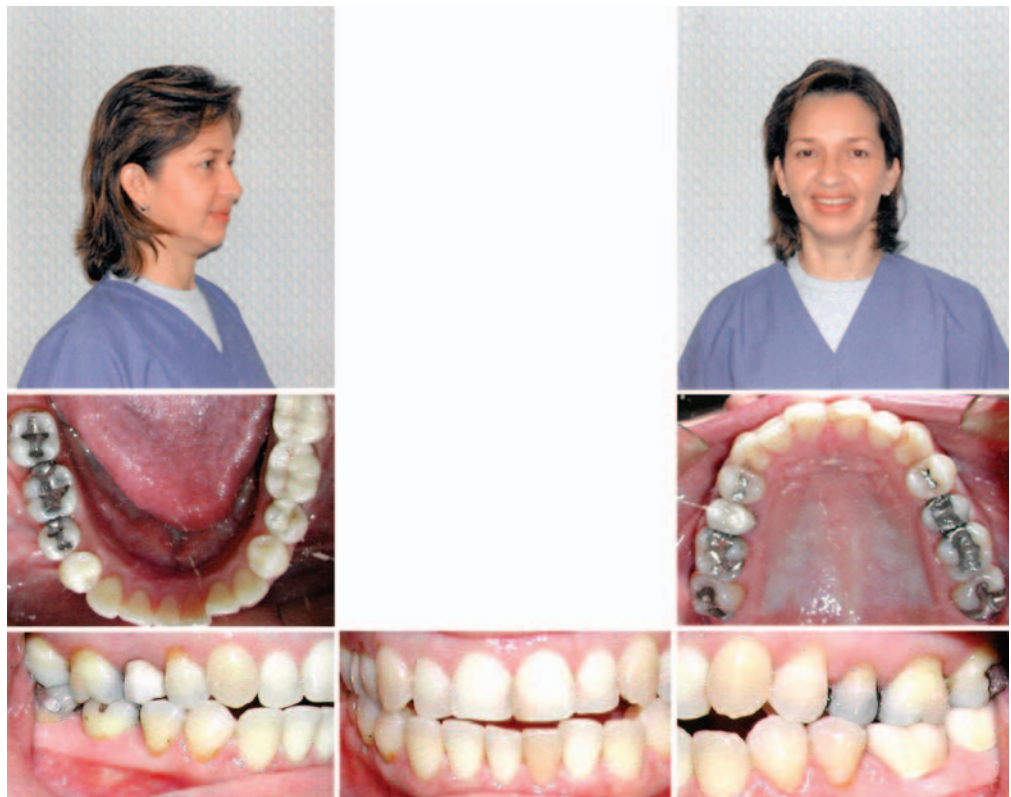Clinical Report (Nicozisis) continued

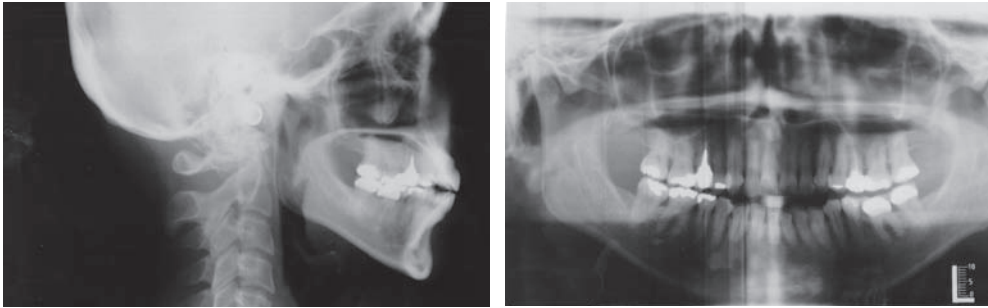
designed to mimic the initial stages of leveling and aligning with a 0.014" NiTi wire. A good default setting for doctor's preferences is: "Create 0.10 mm of space between teeth so there is no interproximal binding during alignment, and then close space with a virtual power chain. I don't want any binding between the teeth during movement." In this fashion any IPR may be performed at the refinement stage, prior to the impression. This is analogous to doing the same procedure at the detailing stages with fixed appliances.

For extrusion cases it is best to design the tooth movements with some principal elements in mind and to communicate those accordingly (keep in mind that we have created space

between the teeth as described above prior to starting extrusion): "When performing extrusion, please make sure there is an equal amount of extrusion occurring with an equal amount of retraction/space closure. Thus, extrusion is occurring at the same time as retraction/space closure. In algebra where  $y = mx + b$  and  $m = \text{the slope}$ , I want a slope of 1/1; an equal component of extrusion for each component of space closure. Make sure there is no interproximal binding between the tooth during extrusion and that extrusion is complete before total space closure." This strategy works well to turn a crowded anterior open bite case into a minor spacing case and then attempt the extrusion as space closure is occurring; sort of a "relative" extrusion.

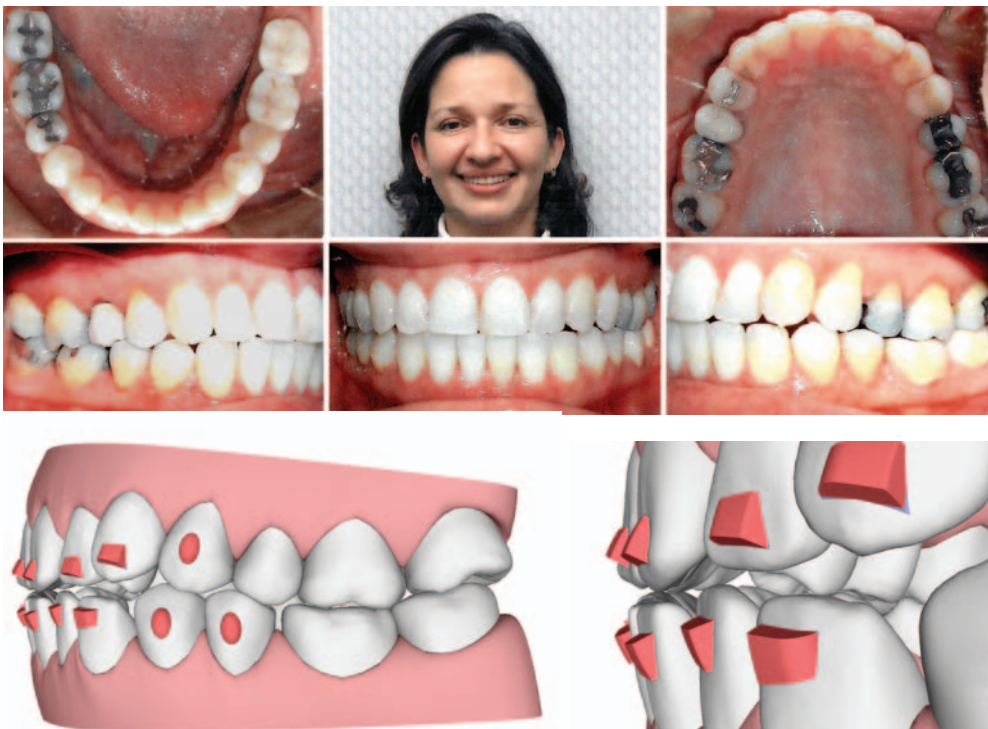
Figure 1a. In this example, the patient presented with a Class I buccal occlusion, 2–3 mm openbite, 0 mm overjet, minor crowding in the lower anterior, moderate crowding in the upper anterior, and crossbite of the left second bicuspids.





Figures 1b, 1c. Her cephalometric image shows a minor Class III skeletal pattern with a dental, not a true skeletal, open bite. There is no canine or incisal protrusive guidance. The panoramic radiograph shows no contraindication to treatment.

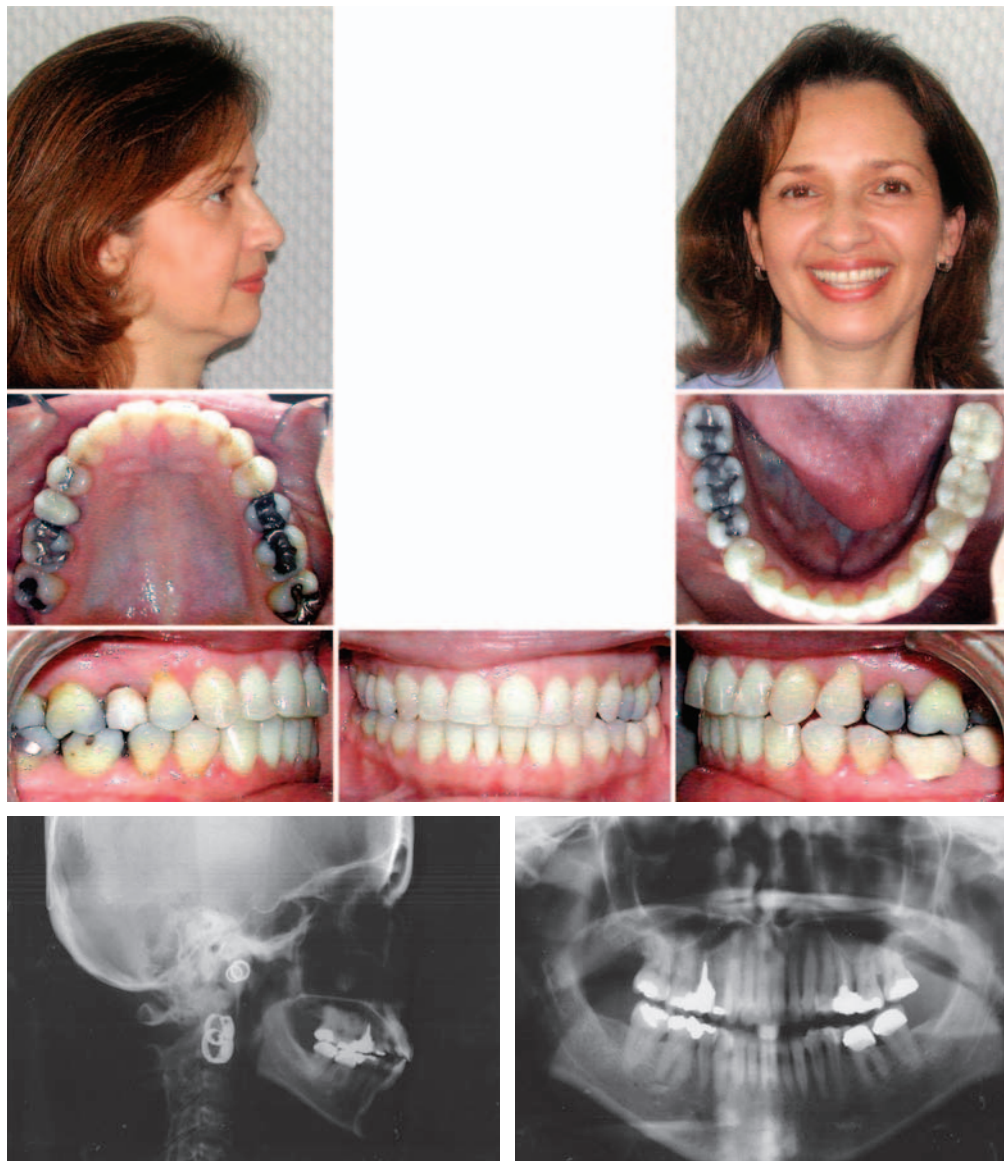In this case, IPR was performed prior to the initial pvs impressions because of her mild Class III skeletal pattern, and take into account the need for space in the lower anterior to create a positive overjet. Tooth movements were prescribed as described above. Ramped attachments were placed on the upper and lower canine-to-canine regions and ellipsoid attachments on the premolars to help stabilize the aligners while extrusion takes place. Attachments bonded 12/2003. The initial ClinCheck suggested 33 aligners in the upper arch, and 28 in the lower.



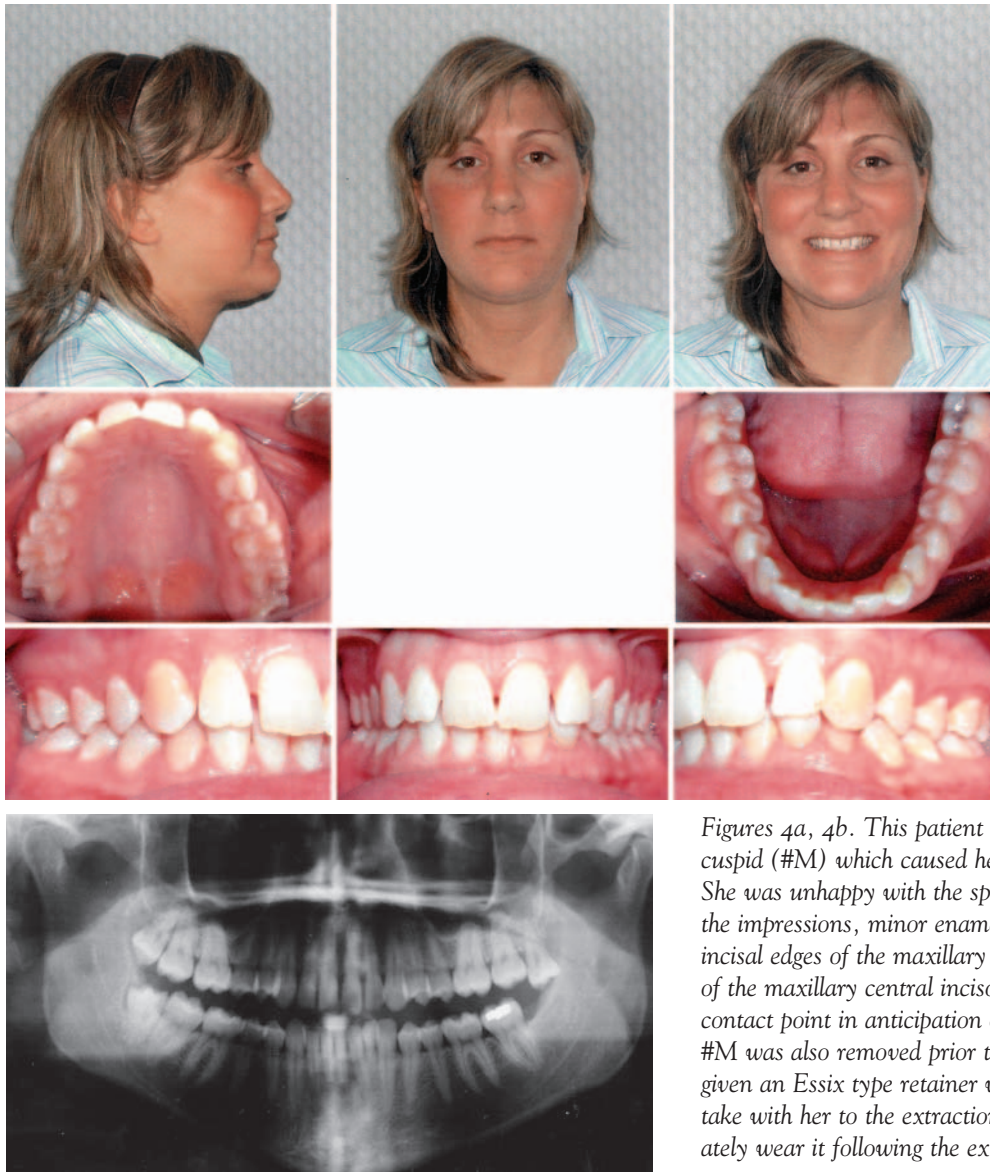Figures 2a, 2b, 2c. Case refinement impressions were made after 14 months at stage #29. Refinement required 5 upper stages plus 5 overcorrection, for a total of 10 (but went only to #8). In the lower, 12 stages plus 3 overcorrection for a total of 15, and we used all 15.

Clinical Report (Nicozisis) continued

Figures 3a, 3b, 3c. Case was completed 1/2006; 25 months of treatment. Retention was with Essix type retainers. Patient now has cuspid and protrusive incisal guidance, with positive overbite and overjet as can be seen clinically and on the cephalometric image.



## Case 2: Extraction

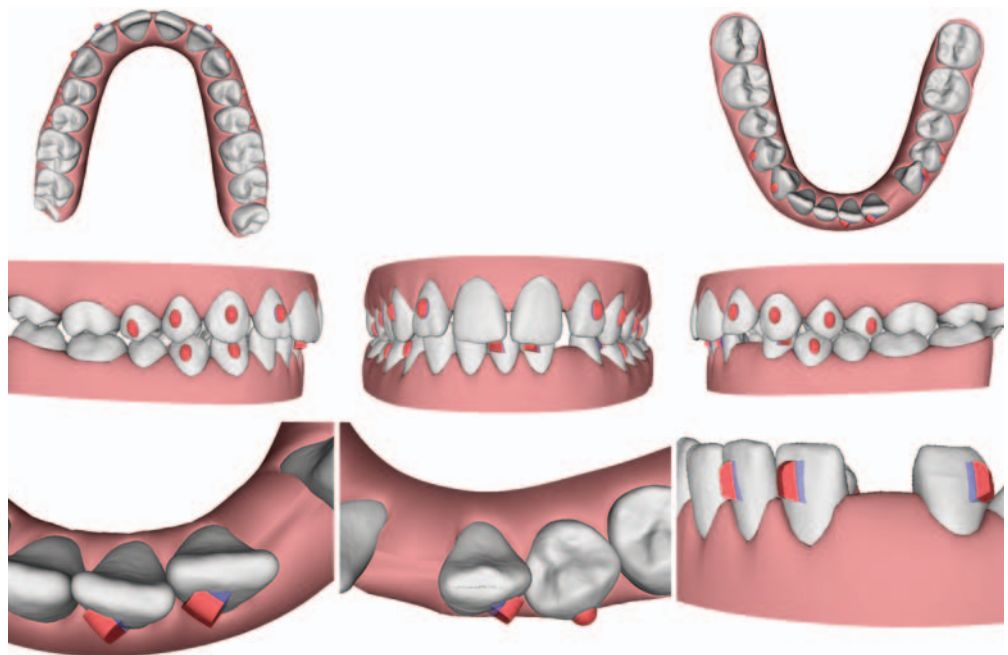


Figures 4a, 4b. This patient had a retained primary lower left cuspid (#M) which caused her lower midline to shift to the right. She was unhappy with the spacing in the upper arch. Prior to the impressions, minor enamelplasty was performed on the incisal edges of the maxillary anterior and on the mesial surfaces of the maxillary central incisors to create a better interproximal contact point in anticipation of space closure. The retained tooth #M was also removed prior to the impression. The patient was given an Essix type retainer with a pontic in the space of #M to take with her to the extraction appointment so she could immediately wear it following the extraction.

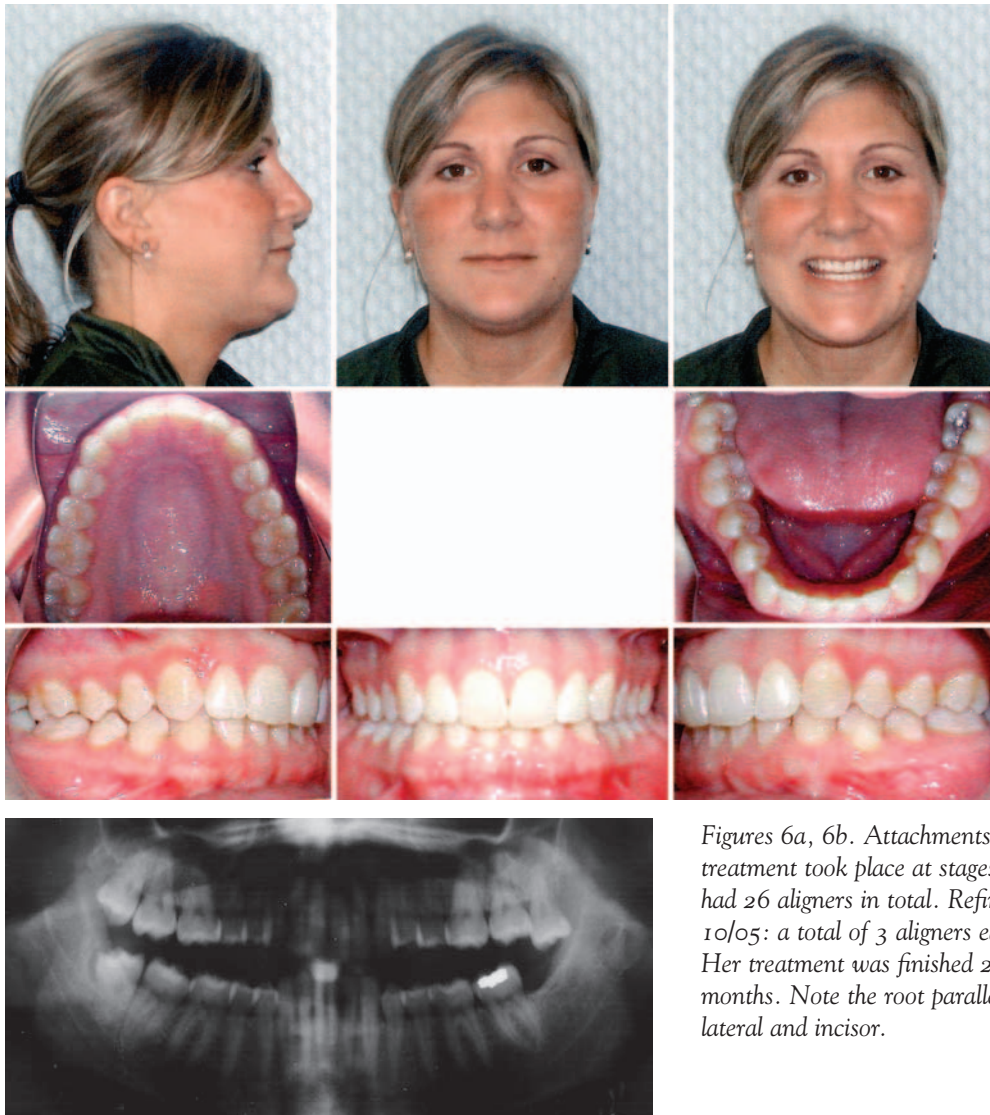Clinical Report (Nicozisis) continued

Her attachments on the teeth being moved into the extraction case were ramped attachments. They were oriented vertically with one caveat: the incisor attachments were placed on the mesial half of the crowns and the cuspid attachment was placed on the distal half of the crown. Why? Because aligners are more effective pushing teeth rather than pulling, if the attachment is placed behind the center of resistance, it elicits better tooth movement as the line of force application will start from behind the center of resistance and go through it, rather than in front of it.

Figure 5. In lower incisor extraction cases, I ask for: “long vertical attachments (3.00 mm long, 1.50 mm wide) 1.25 mm thick on the mesial margin, tapering to a thickness of 0.25 mm on the distal margin. Place on the half of the crown away from the extraction site.” As is evident from the illustration, a ramped attachment in this application allows for more attachment/aligner surface area contact and interaction, as compared to the traditional vertical rectangular attachment.



In her treatment refinement touch-ups were needed only to tighten the interproximal contacts. As is evident in the panoramic image taken at the refinement stage, root parallelism is excellent and did not need to be corrected in refinement. If I were to treat this case again from the beginning, I would have intruded the lower incisors and lower left canine during space closure to help further correct the overbite. As is evident, the patient chose to neglect our recommendation to remove her third molars.



*Figures 6a, 6b. Attachments were bonded 10/04. Upper arch treatment took place at stages 8–26; 19 aligners total. Lower had 26 aligners in total. Refinement impressions were made 10/05: a total of 3 aligners each for upper and lower arches. Her treatment was finished 2/06; total treatment time 16 months. Note the root parallelism between the lower left lateral and incisor.*

These two cases demonstrate that fixed or non-fixed appliances yield similar results if the clinician is equipped with the knowledge of mechanics. In common, both systems “attach” onto a supporting dogma that is as defined as the person searching for more meaning. I have chosen to “attach” my beliefs to the fundamental principles of biological tooth movement regardless of the appliance system chosen.

# CLINICAL REPORTS & TECHNIQUES

Orhan C. Tuncay, DMD, Editor

## IN THIS ISSUE

Letter from the Editor . . . . .	1
Clinical Report by Dr. Paquette . . . . .	2
Clinical Report by Dr. Nicozisis . . . . .	9

*Invisalign® and ClinCheck® are registered trademarks of Align Technology, Inc. All other product names, service marks and trademarks mentioned herein are trademarks of their respective owners. Copyright © Align 2005–2006. All rights reserved. The ideas, opinions, statements and information (“Views”) set forth in this report are the professional opinions of the writer, and Align Technology, Inc. disclaims all liability for such Views.*

